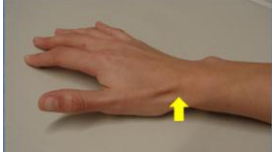


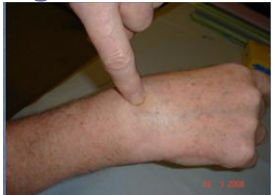Fracture Scaphoid

Incidence: 1.47 per 100,000 person-years



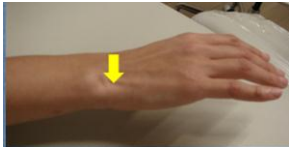Pain in snuff box – Requires fixation of the broken bone

Torn Scapho-Lunate Ligament



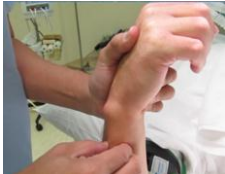Usually due to twisting injury of the wrist, the torn ligament requires repair

TFCC Tears



Torn cartilage is usually after a fall. It can be repaired by keyhole surgery

DRUJ Instability



- Occurs after wrist fracture
- Diagnosis: Pain & stiffness in forearm rotation
- Usually female >60 years old



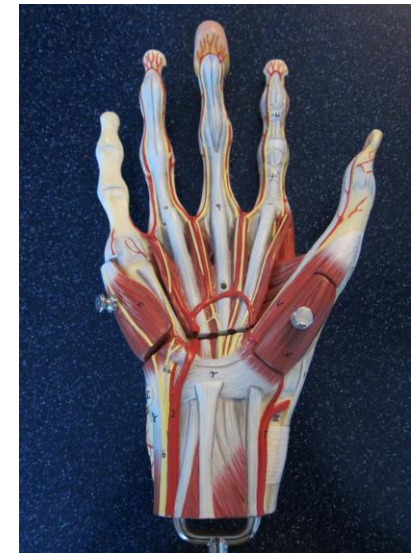Hong Kong Shoulder & Wrist Centre
Suite 2906 Bank of America Tower
12 Harcourt Road
Central, Hong Kong

Tel: +852 2537 8884

Email: info@topshoulder.com.hk
www.topshoulder.com.hk

Hong Kong Shoulder & Wrist Centre

Wrist Pain Made Simple

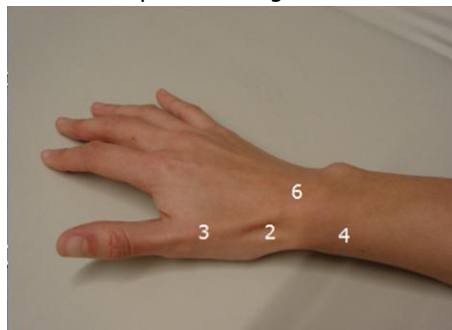


Diagnosis of Wrist Pain

Is the pain on the thumb side or little finger side?

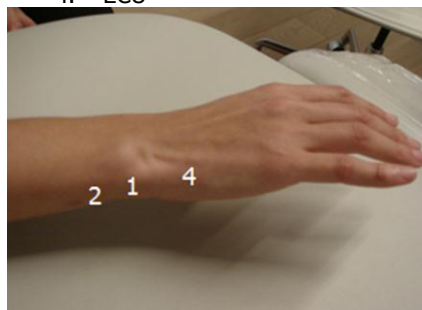
Thumb side (88%)

1. Carpal Tunnel Syndrome
2. Scaphoid Fracture
3. CMC Joint Arthritis
4. DeQuervain
5. Trigger Thumb
6. Scapholunate Ligament Tear

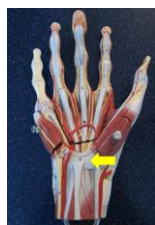

Little Finger Side (12%)

1. TFCC Tear
2. Ulnar Abutment
3. DRUJ
4. ECU



Carpel Tunnel Syndrome

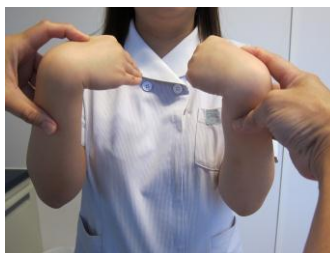

Prevalence 7-16% (UK)

Female between 50-60 years old

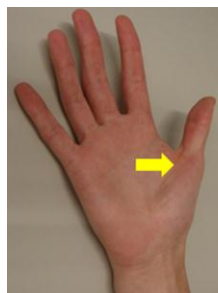
Affected Site: thumb, index, middle and half of ring finger

Phalen's test



If positive, there will be numbness or tingling in the hand or wrist. The testing position should be held for at least 30 seconds.

Trigger Thumb/Finger



FPL degeneration with loss of extracellular matrix

Common 2% risk
Diabetes 10% risk

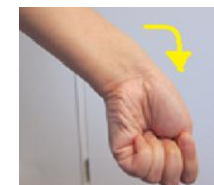
Fifth Decade-
Female to male ratio
6:1

DeQuervain

A painful fusiform swelling noted along the thumb side of the wrist usually associated with repetitive movements.

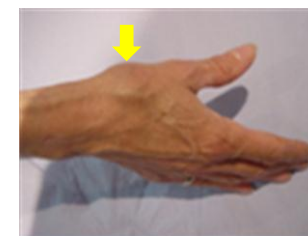Occurrence rate: 2.8 females and 0.6 males per 1,000 person-years.

Finkletein's Test positive for DeQuevain



Worse with thumb movement (See picture above)

CMC Joint Arthritis



Common site of Osteoarthritis

Diagnosis—Local pain

For age > 75 years
Male: 25%
Female: 40%